



Morphological Characteristics of the Pelvis of Adult Chinkara *Gazella bennettii* (Sykes, 1831) (Mammalia: Bovidae)

Din Salahud^{1,*}, Masood Saima¹, Zaneb Hafsa¹, Rehman Habib¹, Khan Imad², Sikandar Arbab¹, Ullah K. Asad², Luqman Zubair³, Masood Ayesha³ & Khan Arsala⁴

¹ Department of Anatomy and Histology, University of Veterinary and Animal Sciences, Lahore, Pakistan

² Abdul Wali Khan University, Mardan, Pakistan

³ University College, University of Veterinary and Animal Sciences, Islamia University of Bahawalpur, Bahawalpur, Pakistan

⁴ Department of Livestock and Dairy Development – Extension, Peshawar, Khyber Pakhtunkhwa, Pakistan

Abstract: The first basic information on gross morphology and anatomical analyses of the pelvis of adult chinkara *Gazella bennettii* is provided. Twenty adult chinkara individuals (ten male and ten female) are studied. The bones of chinkara for osteometric studies were collected from the Manglot Wildlife Park and Ungulate Breeding Centre Nizampur, Khyber Pakhtunkhwa, Pakistan. The pelvis has many anatomical differences compared with other domesticated and wild ungulates such as the presence of tubercle in the iliac crest, shape and orientation of the iliac wings, concavity of the ventral border of the ilium, notches in the acetabulum, location of the obturator foramen and ischiadic tuber as well as specific structure of the sacrum. Significant differences ($P < 0.05$) in osteometrical parameters in the pelvic bones of males and females were observed. The anatomical peculiarities of the pelvis of these animals may be an adaptation for fast running.

Key words: Gross anatomy, morphometry, sexual dimorphism.

Introduction

The chinkara *Gazella bennettii* (Sykes, 1831), also known as Indian gazelle, has six subspecies. Morphological data on it have been provided by GROVES (1969). Chinkara lives in light forests, dry scrub, deserts, hills and dry plains; in Pakistan, it reaches up to an altitude of 1500 m. In India, it occurs in more than 80 protected zones and is well-preserved in the Kavir National Park, Iran (MALLON & KINGSWOOD 2001). However, in Pakistan, Iran and Afghanistan, the chinkara is threatened species due to the widespread hunting for trophies and meat. Other susceptibilities comprise the extension of industries and agriculture, often resulting into habitat loss. This

species has been sheltered at five sites in Pakistan and nine sites in Iran (MALLON 2008).

Animal gross morphological features show significant dissimilarities concerning age, breed, sex, environmental factors and nutritional condition. Biometrical studies have been carried out to obtain a more objective genetic assessment (KUNZEL et al. 2003, BROMBIN et al. 2009). The pelvis is formed by the two os coxae, the sacrum and one or two coccygeal vertebrae. The pelvic inlet or linea terminalis is formed from promonotrium of the sacrum, wing of the sacrum, wing of the ilium or linea arcuate, through eminentia iliopubica and finish with pecten ossis pubis. The outlet is limited dorsally by the cranial coccygeal vertebrae. The left and right os coxae

*Corresponding author: Salahuddin7277@yahoo.com

fused in ventral midline through pelvic symphysis (OZKAN 2002b). The pelvis encloses the birth passageway as a bony ring, and its gross shape and dimensions are of vital importance for normal delivery (DUCE et al. 2002). The shape and the dimensions of the pelvic cavity are utmost important in the time of parturition. In addition, in obstetrics, the length and the location of the sacrum and its ratio to the length of the pelvic cavity are important (NICKEL et al. 2004). As mentioned by DURSUN (2006), space between the left and right os coxae is always greater in females. Sexual dimorphism exists in the size and shape of the pelvis (TAGUE 2003). The transverse diameter, oblique diameter and outlet transverse diameter in male dogs are greater than in female dogs (SAJJARENGPONG et al. 2003). It is observed in many terrestrial mammals that the increase in the width of the iliac wing is the capability to perform powerful leaps (SARGIS 2002). The wide iliac wing creates the expanded surface for the connection of the gluteus medius muscle, one of the most powerful thigh extensors; the iliac crest is the attachment position for the muscle gluteobiceps; it is also a hind limb extensor (ARGOT 2002).

Osseous remains of these antelopes are often encountered but their specific identification poses considerable problems. The present authors have expected gross anatomical and osteometric differences with other related wild and domesticated ungulates. Therefore, this study was designed to obtain basic information about the anatomy of the pelvis, to thoroughly describe and investigate the osteomorphometric (gross morphological and morphometric study) features in this species.

Materials and Methods

Animals and sample collection

Twenty adult chinkara (10 males and 10 females) specimens from the same locality were studied. The pelvic bones were collected from the graveyard of Manglot Wildlife Park and Ungulate Breeding Centre, Nizampur, Khyber Pakhtunkhwa, Pakistan. The age and sex of the animals were obtained from the wildlife park record. The measurements were carried out with the help of digital callipers. Each measurement was reiterated three times by two independent observers and the mean value was used in the analyses. The nomenclature of NOMINA ANATOMICA VETERINARIA (2012) was used.

Osteometric parameters

The following parameters of the pelvis were measured: a. Transverse diameter (Dt), inter psoas tuber-

cle diameter (Fig. 1); b. Conjugate diameter (Dc), distance between the sacral promontory to pectineus pubis; c. Length of pubic symphysis (Lps) (Fig. 1); d. Length of obturator foramen (OL) (Fig. 2) and acetabulum (Fig. 4) (Cranio-caudal distance); e. Diameter of obturator foramen (OD) (Fig. 2) and acetabulum (Fig. 4) (dorsoventral distance) and depth of acetabulum. The measurements of the Os coxae were as follows: length of Os coxae (LoC), length of the ilium (LiL), width of the ilium (WiL), width of the body of ilium (WbiL), length of the ischium (LoI), distance from the caudal boundary of obturator foramen to the ischiatic arch (CdOFISA), distance from the cranial boundary of the obturator foramen to the pecten (CrOFP).

Statistical design

All anatomic values were expressed as the mean \pm standard deviation (SD) and the means of male and female specimens were compared with a Student t-test. The analysis of data was conducted using SPSS version 20.0 (SPSS, Inc., Chicago, IL) and differences were considered significant at $P < 0.05$.

Results

General morphology of pelvis

Ilium. Both ilia were almost parallel to each other in compliance with the horizontal plane and had a narrow space dorsally between the tuber sacralia. The ilium was the largest bone of the os coxae and placed dorsocranially. The wings of the ilium were with rectangular shape in both dorsocranial and lateromedial view; the body was flattened. The iliac crest was divided into dorsal and ventral parts by centrally laying prominent tubercle; the dorsal part was convex and arched medially while the ventral part was almost straight (Fig. 3). The cranioventral angle of the tuber coxae was pointed, sharp and extended below the level of the ventral border; however, the dorsomedial end of the tuber sacrale or spina iliaca dorsalis cranialis were not visible as separate entities. The dorsal border of the wing of the ilium was coursed obliquely from the spina iliaca cranialis to spina iliaca dorsalis (Fig. 1). The ventral border of the body of iliac bone was deeply concave from the cranial ventral iliac spine to the acetabulum (Fig. 2). The facies glutea of the wing of the ilium was divided into dorsal and ventral parts by horizontal linea glutea ventralis. The linea glutea ventralis extended from the middle of the iliac crest up to the level of the ischiatic spine. The surface dorsal to the linea glutea ventralis was concave, placed medial to the linea glutea ventralis and forming a perfect triangle;

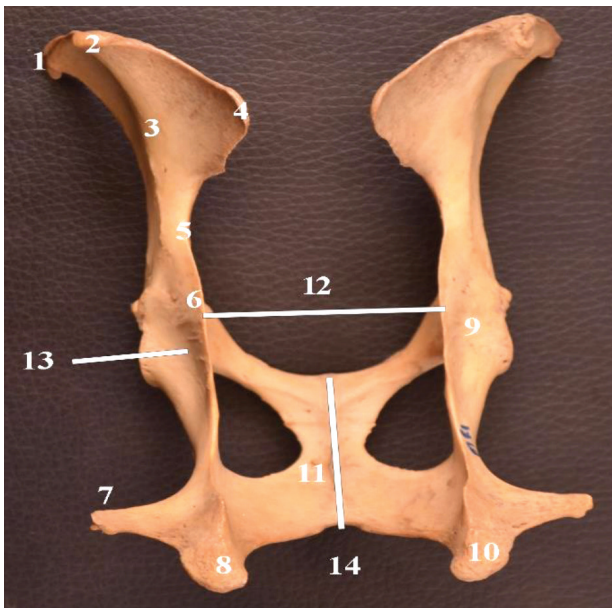


Fig. 1. Dorsal view of the os-coxae of chinkara showing tuber coxae continue with spina ilica cranialis ventralis (1); iliac crest tubercle (2); line glutea ventralis (3); spina iliaca dorsalis cranialis (4); greater ischiatic notch (5); ischiatic spine (6); parts of the tuber ischiadicum (7, 8, 10); acetabulum (9); ischial arch (10); length of the pubic symphysis (11), diameter transversa spina ischiadica (12), muscular lines (13); ischial arch (14).

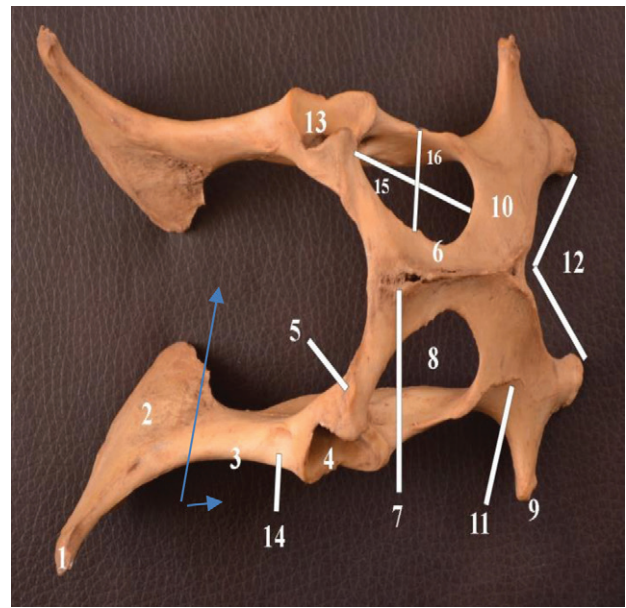


Fig. 2. Ventral view of the os-coxae of chinkara showing tuber sacrale (1); facies auricularis (2); ventral border of the body of the ilium (3); eminentia iliopubica (4); iliopectineal eminence (5); caudal branch of the pubic bone (6); tuberculum pubicum ventrale (7); obturator foramen (8); tuber ischiadicum lateral tip (9); tabula ossis ischii (10); curved muscular line (11); ischiatic arch (12); acetabular fossa (13) area medialis m. recti femoris (14); tuber coxae body of ilium (14); length (15) and width (16) of the obturator foramen.

this might be for the attachment of *m. gluteus medius* (Fig. 3). The medial surface (facies sacropelvicina) of the wing of the ilium was rough, convex and faced to one another. Outside of the triangular facies auricularis, surface was rough, forming tuberosities iliaca. The body of the ilium was compressed laterally. The greater ischiatic notch was narrow, deep and thick compared to the tuber sacrala (Fig. 3).

Ischium. The ischium was located caudally and entered into the formation of the acetabulum, obturator foramen, ischial arch and pelvic symphysis (Fig. 1). The tuber ischiadicum was of triangular shape and truncated appearance (Fig. 3). The caudal border of the tuber ischiadicum was projected medially over the ischial arch. A pronounced lateral hook like an extension from the tuber ischiadicum was a unique feature in these animals. The ischiatic arch was smooth, deep but narrow and perfectly V-shaped in both males and females (Fig. 2). The ischiatic tables on the dorsal surface were flat, concave and positioned inclined and oblique to the pelvic symphysis. A curved prominent muscular line (attachment area for *m. adductor* and extrapelvic part of the *m. obturatorius externus*) was present in the middle of the ventral surface of the ischiatic tables, which was

thick near to the caudolateral brim of the obturator foramen and taper towards the ischiatic tuberosities. The body of the ischium was compressed laterally and tilted over the obturator foramen. A prominent muscular ridge was noticed on the medial surface of the body of the ischium, extending from the cranio-lateral brim (attachment area for *m. quadratus femoris*) of the obturator foramen to the lesser ischiatic notch (Fig 2). The ischiatic spine was in the form of an extended crest, having visible and dense muscular lines on the lateral side (Fig. 3).

Pubis. The pubis was the smallest bone of the os coxae located between the ilium (cranially) and ischium (caudally). The body of the pubis was located cranially to the obturator foramen and placed obliquely between the acetabulum and pubic symphysis. The pecten ossis pubis was sharp and smooth; the eminentia iliopubica were well prominent (Fig. 1). The tuberculum pubicum was in the form of sharp projection cranially from the midline pelvic symphysis. The obturator sulcus was a deep and smooth groove, oriented caudally in the dorsal surface of the caudal ramus (ramus caudalis ossis pubis). The caudal boundary of the pubic body was rounded; however, it was sharp on the pubic rami.

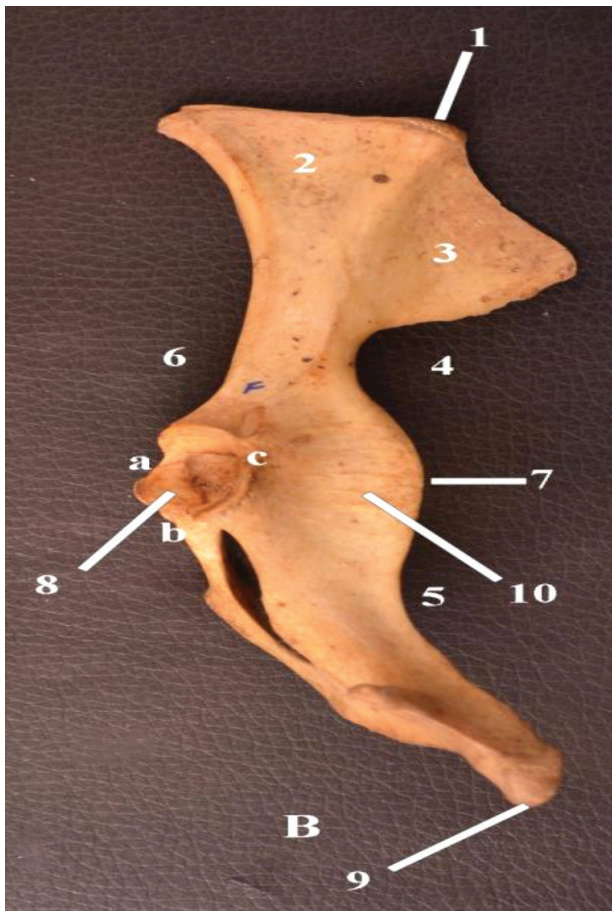


Fig. 3. Lateral view of the os-coxae of adult chinkara showing iliac crest (1); ventral and dorsal part on the lateral surface of the ilium (2,3); greater ischiatic notch (5); lesser ischiatic notch (5); ventral border of the ilium (6); ischiatic spine (7); facies lunata (8); tuber ischadicum (9); muscular lines (10); and acetabular notches (a,b,c).

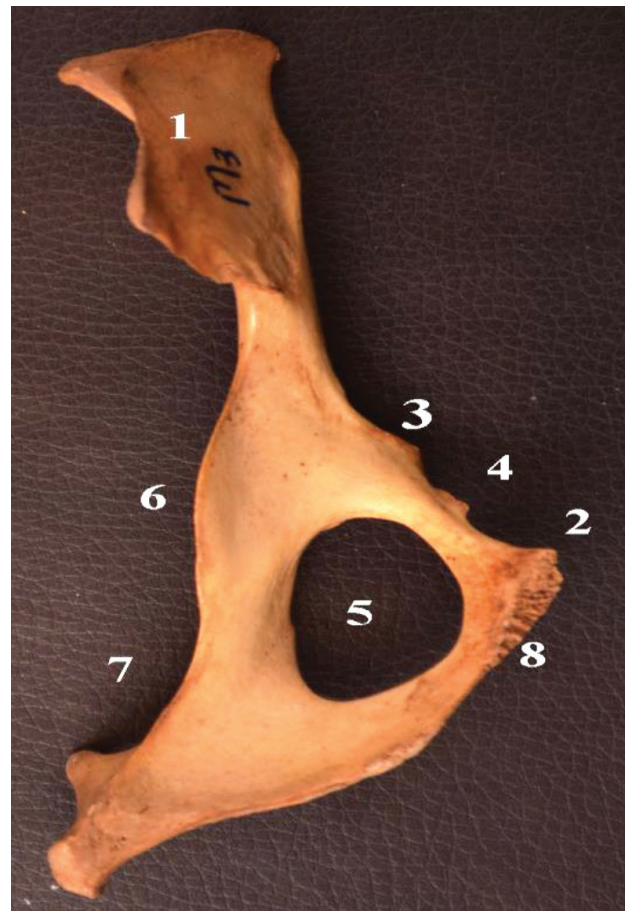


Fig. 4. Medial view of the os-coxae of the adult chinkara showing facies sacropelvina (1), pecten ossis pubis (2), Iliopubic eminence (3), eminencia iliopubica (4), obturator foramen (5), Ischiatic spine (6), lesser ischiatic notch (7), ramus caudalis ossi pubis (8).

For measurements, see Table 1. The mean greatest length of the pubic symphysis in males was significantly longer than in females ($P < 0.05$).

Acetabulum. The acetabulum was located laterally in the middle of the os coxae and was shaped by the merging of the bodies of three bones, i.e. ilium, pubis and ischium (Fig. 3). It had three notches; the caudomedial notch was deeper, the craniomedial and lateral notches were small and shallow (Fig. 3). The concentric surface (facies lunata) appeared as discontinued ventrally and caudally at the level of the caudomedial notch (Fig. 3). The lips of the acetabulum were wide. The non-articular surface of the acetabulum was rough, with triangular shape, and communicated through incisura acetabuli with the obturator foramen. For measurements, see Table 1.

Obturator foramen. The obturator foramen was situated on the floor of the pelvis. It was oval-shaped opening and was moulded by the ischium

and the pubis (Fig. 2). It was located more cranially towards the pelvic inlets. For measurements, see Table 1.

Sacrum. The sacrum was triangular and had four segments. The vertebral bodies and spinous processes were completely fused to form a single bone (Fig. 5). The sacrum had two surfaces, two borders, a base and an apex. The base was the cranial extremity of the first sacral vertebrae; on the lateral parts of the base, a quadrilateral-shaped sacral wing was identified. These sacral wings (ala sacralis) were greater in height than in width; their dorsal surface was rough, bearing a triangular area, the auricular face, on its lower part for articulation with the ilium. The dorsal articular surfaces of the sacral wings faced laterally. Cranially, the vertebral body of the first vertebra was flattened ventrally and had a transversely elongate convex surface (sacral promontory) for articulation with the caudal fossa vertebrae of the body of the last lumbar vertebrae

Table 1. Measurements of os coxae of adult chinkara (cm).

Characters	Male	Female	P-value	
	Mean±SD	Mean±SD		
Transverse diameter (Dt)	6.57±0.03	6.94±0.16	0.00	
Conjugate diameter (Dc)	6.03±0.04	6.24±0.15	0.02	
Acetabulum	Diameter	2.35±0.13	2.59±0.16	0.40
	Length	2.54±0.11	2.54±0.31	0.19
	Depth	1.54±0.21	1.23±0.10	0.53
Obturator foramen	Length (OL)	3.98±0.28	3.70±0.07	0.86
	Diameter (OD)	2.68±0.15	2.39±0.09	0.04
Length of pubic symphysis	5.43±0.20	5.10±0.54	0.00	

Differences were considered significant at $P < 0.05$

(Fig. 5). The dorsal surface of sacrum was arched, giving a convex appearance, and had a median sacral crest, lateral sacral crests and three pairs of dorsal sacral foramina. The spinous processes were completely fused to form the median sacral crest in adult individuals. Cranially, the median sacral crest was lengthy and had thin summit while it was thick and low caudally. Crista sacralis lateralis were formed from the fused transverse process on either side of the median sacral crest. The cranial two pair of dorsal sacral foramina were present in the groove on either side of the median sacral crest while the third sacral foramen was between median crest and intermediate crest. A small foramen pierced the lateral sacral crest at the level of the second dorsal sacral foramen and opened into it. Similarly, another small foramen was present in the groove at the level of the third dorsal sacral foramen and opened into it (Fig. 5).

The ventral surface (Facies pelvina) was smooth and concave in both directions and had three transverse lines, which marked the fusion of the sacral vertebrae. The ventral surface was wide cranially and narrowing caudally. Three pairs of ventral sacral foramina opened into the neural canal. The first pair of the sacral foramina were quadrilateral while the second and third pair were elongate in shape. The ventral sacral foramina were larger in diameter than the dorsal and decreased in size from the first to the last pair. The cranial articular processes were quadrilateral in outline and were large and concave medially and convex laterally. The center articular surfaces were directed medially and articulated with the last lumbar vertebra. Slightly caudal to the articular process on either side, notches were observed, which were prominent, triangular and smooth. The apex was the caudal aspect of the sacrum, quite small (Fig. 6). The sacral canal was the part of the vertebral ca-

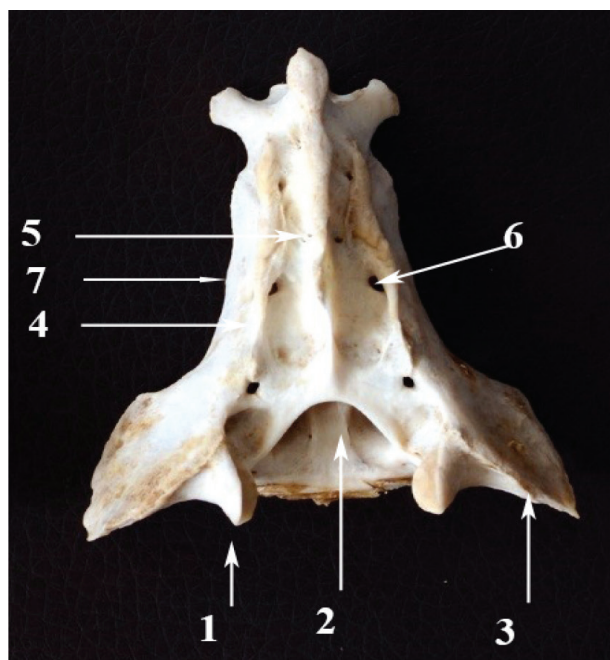


Fig. 5. Dorsal view of the chinkara sacrum showing cranial articular process (1), canalis vertebralis (2), ala sacralis (3) crista sacralis intermedia (4), median sacral crest (5), dorsal sacral foramen (6).



Fig. 6. Ventral view of the chinkara sacrum showing wing of the sacrum (1), crista sacralis lateralis (2), caudal border of the last sacral vertebra (3), foramen sacralis ventralis (4).

nal, which crossed the sacrum; its cranial part was large and slowly decreasing in depth and width in caudal direction. It was triangular both cranially and caudally. Above the neural ring, there was a pointed projection of the caudal end of the median sacral crest. The lateral borders were thin and irregular throughout its length.

Osteometric studies

No statistically significant differences were detected for the majority of the measured osteometric parameters of the sacrum of male and female adult chinkara (Tables 1–5). The only exceptions were the body length of sacrum, median sacral crest length, median sacral crest height at the base, the distance between lateral and medial sacral crests at base and apex, the distance between two cranial articular processes (of S1) on the dorsal surface, the

distance between right sacral foramen from right lateral border dorsal (3), the distance between right sacral foramen from right lateral border ventral (1) and distance between left sacral foramen from left lateral border dorsal (1). In the present study, the body of the sacrum is significantly higher in female chinkara than in males.

Discussion

This is the first comprehensive study of the gross anatomical features and the osteometry of the pelvis of adult chinkara. The pelvis encloses the birth passageway as a bony ring, and its gross shape and dimensions are of vital importance for normal delivery (DUCE et al. 2002). In addition to the importance of the pelvis in body scaffolding and understanding the delivery apparatus of the chinkara, this study will potentially aid in the forensic examination of the chinkara and related species.

In previous literature (DURSun 2006), space between the left and right os coxae is always higher in females. TAGUE (2003) documented that males, having a large body size in a general sense, have a larger pelvis than the counterpart females; however, females of the same age and size have a comparatively larger pelvis than males, thus showing sexual

Table 2. Measurement of os coxae of adult chinkara (cm).

Characters	Male±SD	Female ±SD	P-value
LOC	17.85±0.10	15.42±0.18	0.360
LiL	8.85±0.11	8.12±0.15	0.125
WiL	7.18±0.05	7.03±0.10	0.172
WbiL	1.84±0.03	1.73±0.04	0.487
LoI	8.68±0.05	7.82±0.08	0.166
CdOFISA	2.54±0.04	2.36±0.05	0.501
CrOFFP	1.09±0.04	1.16±0.06	0.281

Legend: Length of Os coxae (LoC), length of the ilium (LiL), width of the ilium (WiL), width of the body of ilium (WbiL), Length of ischium (LoI), Distance from the caudal boundary of obturator foramen to the ischiatic arch (CdOFISA), Distance from the cranial boundary of the obturator foramen to the pectin (CrOFFP).

Table 3. Measurements of sacrum of adult chinkara (N= 20, cm).

Characters		Female±SD	Male±SD	P-value	
Body	Length	6.44±0.15	5.87±0.03	0.010	
	Width	Base	2.29±0.04	2.49±0.03	0.404
		Apex	0.87±0.05	1.18±0.03	0.105
Diameter of sacral canal	Vertical	Base	1.29±0.05	1.50±0.04	0.215
		Apex	0.56±0.05	0.86±0.04	0.432
	Transverse	Base	1.82±0.04	1.94±0.05	0.828
		Apex	0.98±0.04	1.18±0.03	0.184

Table 4. Measurements of sacrum of adult chinkara (N= 20, cm).

Characters		Female±SD	Male±SD	P-value
Diameter of dorsal sacral foramen	First	0.32±0.04	0.44±0.04	0.569
	Second	0.29±0.04	0.32±0.04	0.843
	Third	0.23±0.03	0.33±0.04	0.385
Distance between the adjacent dorsal sacral foramina	First-second	1.38±0.04	0.97±0.03	0.094
	Second-third	1.46±0.03	1.41±0.03	0.913
Diameter of ventral sacral foramen	First	0.81±0.05	0.69±0.04	0.260
	Second	0.78±0.04	0.66±0.05	0.309
	Third	0.37±0.04	0.37±0.04	0.928
Distance between the adjacent ventral sacral foramina	First-second	0.61±0.04	0.65±0.04	0.625
	Second-third	1.05±0.04	0.91±0.04	0.187

Table 5. Measurements of sacrum of adult chinkara (N= 20, cm).

Characters		Female±SD	Male±SD	P-value	
Width of wings of sacrum		2.30±0.72	1.89±0.03	0.049	
Thickness of median sacral crest	Base	0.14±0.04	0.14±0.04	0.872	
	Middle	0.44±0.03	0.36±0.04	0.629	
Median sacral crest	Length	5.29±0.03	5.49±0.04	0.053	
	Height	Base	1.00±0.03	0.79±0.04	0.051
		Middle	2.08±0.04	2.02±0.04	0.655
		Apex	0.68±0.03	0.71±0.02	0.601
Length of lateral sacral crest		4.26±0.03	4.16±0.04	0.263	
Distance between lateral and medial sacral crests	Base	1.31±0.04	1.46±0.04	0.031	
	Apex	0.60±0.04	0.87±0.04	0.042	
Distance of 4th sacral foramina from apex	Dorsal	1.82±0.04	1.73±0.04	0.439	
	Ventral	1.73±0.02	1.51±0.03	0.109	
Distance of 1st sacral foramina from base	Dorsal	0.87±0.04	2.17±0.04	0.514	
	Ventral	1.54±0.03	1.31±0.05	0.275	
Distance between two ventral sacral foramina of same sacral segment	S1	1.64±0.04	1.49±0.04	0.868	
	S2	1.46±0.04	1.26±0.04	0.856	
	S3	1.05± 0.04	0.95± 0.05	0.141	
Distance between two cranial articular processes (of S1)	Dorsal	2.52±0.01	2.36±0.05	0.000	
	Middle	2.68±0.04	2.89±0.04	0.743	
	Ventral	2.43±0.04	2.49±0.03	0.207	
Length of ventral groove		5.93±0.03	6.03±0.03	0.618	
Distance between right sacral foramen from right lateral border	Dorsal	1	0.70±0.03	0.78±0.03	0.719
		2	0.34±0.04	0.28±0.03	0.837
		3	0.19±0.03	0.24±0.01	0.006
	Ventral	1	1.59±0.03	0.78±0.04	0.023
		2	0.75±0.04	0.45±0.03	0.232
		3	0.67±0.03	0.43±0.04	0.214
Distance between left sacral foramen from left lateral border	Dorsal	1	0.50±0.03	0.81±0.06	0.037
		2	0.42±0.03	0.31±0.03	0.775
		3	0.20±0.03	0.21±0.02	0.517
	Ventral	1	1.89±0.04	0.69±0.03	0.678
		2	0.70±0.03	0.41±0.03	0.722
		3	0.44±0.04	0.34±0.03	0.861

dimorphism in the size and shape of the pelvis. In the present study, similar observations are seen in the pelvimetry of the chinkara. The mean transverse and conjugate diameters of the pelvis of female and male chinkara is 6.57 ± 0.03 cm and 6.94 ± 0.16 cm compared to 6.03 ± 0.04 cm and 6.24 ± 0.15 cm, respectively ($P < 0.05$). However, YADAV et al. (2012) have reported higher values of the same dimensions from the chital without discrimination between sexes, 7.20 ± 0.11 cm and 7.89 ± 0.27 cm, respectively. Similarly, CHOUDHARY & ISHWER (2016) reported in blackbuck 7.27 ± 0.02 cm and 13.24 ± 0.02 cm, respectively. Similarly, in another group of mammals,

NWOHA (2000) has found that in bats the pelvic cavity in females is much wider than in males. In contrast, SAJJARENGPONG et al. (2003) have reported that the transverse diameter, oblique diameter and outlet transverse diameter in male dogs is higher than in female dogs.

It is observed in many terrestrial mammals that the increase in the width of the iliac wing is associated with the capability to perform powerful leaps (SARGIS 2002). The wide iliac wing creates the expanded surface for the connection of the gluteus medius muscle, one of the most powerful thigh extensors; the iliac crest is the attachment position

for the gluteus superficialis muscle, which is also a hind limb extensor (ARGOT 2002). In the present study, it is the largest among the three bones of the os coxae and is unevenly triangular in contour, flat, and extended dorsally, narrow in the middle and slightly expanded below as documented in yak *Bos grunniens* (see SUDHAKAR et al. 1997), other ruminants (FRANDSON et al. 2009), chital *Axis axis* (YADAV et al. 2012), dog (MILLER et al. 2013) and blackbuck *Antilope cervicapra* (CHOUDHARY & ISHWER 2016).

In the present study, iliac crest tubercle is observed in chinkara; however, the same structure has not been documented in many other representatives of the family Bovidae (GETTY 1975). In the cattle, as well as in carnivores, the tuber sacrale has two eminences, the spina iliaca dorsalis cranialis and caudalis (KONING & LIEBICH 2006); the same eminences are also present in chinkara.

In our study, the linea glutea ventralis extends ventrally, similarly to the reports by GETTY (1975) for horse, SUDHAKAR et al. (1997) for yak, YADAV et al. (2012) for chital, MILLER et al. (2013) for dog and CHOUDHARY & ISHWER (2016) for blackbuck. A well prominent linea glutea ventralis has been observed in yak (SUDHAKAR et al. 1997), ox (GETTY 1975) and non-descript goats (CHOUDHARY et al. 2018). However, its prominence and orientation have not been described in small and large ruminants. In ilium, the nutrient foramen is positioned on the gluteal line adjacent to the ventral border. However, contrary to the present study, the nutrient foramen has been reported close to the ischiatic border of the body of the ilium in yak (SUDHAKAR et al. 1997). The proximal part of the pelvic surface is wider and represented a triangular auricular facet in dromedary *Camelus dromedarius* (SMUTS & BEZUIDENHOUT 1987), chital (YADAV et al. 2012) and blackbuck (CHOUDHARY & ISHWER 2016).

The dorsal surface of the pelvic floor of the ischium in chinkara is deeply concave. It is similar to that described by YADAV et al. (2012) in chital, MILLER et al. (2013) in dog and CHOUDHARY & ISHWER (2016) in blackbuck. The general morphology of the chinkara pubis studied is similar to those of other ruminants. The pubis is unevenly deltoid, placed between the ilium (cranially) and ischium (caudally) and is the smallest among the bones of the os coxae, as noted by AKERS & DENBOW (2008) in domestic animals, FRANDSON et al. (2009) in ruminants, YADAV et al. (2012) in chital, MILLER et al. (2013) in dog and CHOUDHARY & ISHWER (2016) in blackbuck; however, it is reported as a curled bone in the horse (GETTY 1975).

The mean greatest length of the pelvic symphysis in the male and female chinkara is 5.43 ± 0.20 cm and 5.10 ± 0.54 cm, respectively, which is significantly ($P < 0.05$) higher in males than females. Further study needed to carry out about the length of the pubis in different age and sex of animals and its implications in parturition.

In the chinkara, the acetabulum has three notches, with the caudomedial notch being deeper and the craniomedial and lateral notches being small and shallow. These anatomic features are similar to other related wild ungulates, i.e. chital (YADAV et al. 2012) and blackbuck (CHOUDHARY & ISHWER 2016).

The margo acetabuli in chinkara are wide and the craniolateral and caudolateral lips are larger than the caudomedial lip. These features may be an adaptation for a wide range of motion and great jump range in these animals. However, further studies concerning femoral head are needed in these animals to elucidate its role in fast running and jumping. The average diameter, length and depth of acetabulum in male and female chinkara are 2.35 ± 0.13 cm and 2.11 ± 0.18 cm, 2.54 ± 0.11 cm and 2.23 ± 0.15 , and 1.54 ± 0.21 cm and 1.50 ± 0.20 cm, respectively. The same parameters calculated in blackbuck (CHOUDHARY & ISHWER 2016) are 2.50 ± 0.009 cm, 2.79 ± 0.01 cm and 1.42 ± 0.004 cm, respectively. These differences in the diameter, length and depth of acetabulum as well as in the acetabular gross anatomy within wild and domestic ruminants may have a connection in the stability of the hip joint, joint range motion and weight dissemination during propulsion.

The obturator foramen placed on the floor of the pelvis is a large oval-shaped opening; it is moulded by the ischium and the pubis as shown by GETTY (1975) in the horse, YADAV et al. (2012) in chital and CHOUDHARY & ISHWER (2016) in blackbuck. VENTURA et al. (1991) have reported that the obturator foramen is triangular in female and semicircular in male voles. The obturator foramen in chinkara is located more cranially to the pectin; however, its position in the pelvic floor in other animals is not reported. Furthermore, it is important to study its location in the pelvic cavity concerning its impact in breeding, parturition and postpartum change in animals. The measurements of the location of the obturator foramen have vital importance in the pelvic cavity because the obturator nerve and vessel pass through it. In ruminants, crista sacralis intermedia is present that represents the fused articular process (KONING & LIEBICH 2006). The same morphological feature is also observed in this study in chinkara. The average length (OL) and diameter

(OD) of the obturator foramen in male and female adult chinkara is 3.98 ± 0.28 cm and 3.61 ± 0.28 cm, and 2.68 ± 0.15 cm and 2.33 ± 0.23 cm, respectively. Nearly matching values (3.75 ± 0.01 cm and 2.62 ± 0.01 cm, respectively) are reported in blackbuck (CHOUDHARY & ISHWER 2016). (NAHKUR et al. (2003) reported that in elks the size of the obturator foramina is comparable to that of the medieval cow. OL and OD in the current study are higher in male chinkara than in females. However, VENTURA et al. (1991) reported that in voles the average value of the length of the obturator foramen in females is higher than in males, which is in contrary to our results. From the present study, we may conclude that the OL and OD shape and size vary in different animals.

Conclusions

There are no previous studies on the gross morphological and osteometric data of the pelvis of the chinkara. The present study provides baseline data and an initiation for further interdisciplinary studies by anatomists, archaeozoologists, biologists, hunting researchers and forensic scientists. Furthermore, in this research, osteometrical data have derived from modern populations; they can be compared with ancient animal populations in archaeozoological assessments. However, this study describes an important initial step only. More data regarding different age group and in different environmental condition have to be assembled. This will prove valuable in other studies of bovids.

Conflict of interest: The authors have declared no conflict of interest.

References

- AKERS R. M. & DENBOW M. 2008. Anatomy and physiology of domestic animals. First Edition. Ames, Iowa: Blackwell, pp. 152–160.
- ARGOT C. 2002. Functional adaptive analysis of the hindlimb anatomy of extant marsupials and the paleobiology of the Paleocene marsupials *Mayulestes ferox* and *Pucadelphys andius*. *Journal of Morphology* 253: 76–108.
- BROMBIN C., MO G., ZOTTI A., GIURISATO M., SALMASO L. & COZZI B. 2009. A landmark analysis based approach to age and sex classification of the skull of the Mediterranean monk seal *Monachus monachus* Hermann, 1779. *Anatomia, Histologia, Embryologia* 38: 382–386.
- CHOUDHARY O. P. & ISHWER S. B. 2016. Gross morphometrical studies on pelvic girdle of Indian blackbuck (*Antelope cervicapra*). *Indian Veterinary Journal* 93 (6): 48–51.
- CHOUDHARY O. P., KALITA P. C., DOLEY P. J., KALITA A. & ARYA R.S. 2018. Morphological and morphometrical studies on the pelvic girdle of goat in mizoram. *Indian Journal of Small Ruminants* 24(2): 346–349.
- CLUTTON-BROCK J., DENNIS-BRYAN K., ARMITAGE P. L. & JEWELL P. A. 1990. Osteology of the Soay sheep. *Bulletin of the British Museum (Natural History), Zoology* 56: 1–56.
- DUCE K. M., SACK W. O. & WENSING C. G. 2002. Textbook of veterinary anatomy. Third Edition. Philadelphia: Saunders Company.
- DURSUN N. 2006. *Medisan Yayın*, Ankara, Turkey, *Veteriner Anatomi* 1: 11.
- FRANDSON R. D., WILKE W. L. & FAILS A. D. 2009. Anatomy and physiology of farm animals. Seventh Edition. Ames, Iowa: Blackwell, pp: 133–135.
- GETTY R. 1975. Equine and ruminant osteology. In: GETTY R. (Ed.) *Sisson and Grossman's "The anatomy of the domestic animals"*, Vol. 1. Fifth Edition. Philadelphia: W.B. Saunders. pp. 273–317.
- GROVES C. P. 1969. On the smaller gazelles of the genus *Gazella* de Blainville, 1816. *Zeitschrift für Säugetierkunde* 34(1): 38–60.
- GUINARD C. & LALLEMAND M. 2003. Osteometric study of metapodial bones in sheep (*Ovis aries* L. 1758). *Annals of Anatomy* 185: 573–583.
- HOWARD E. E. & ALEXANDER D. L. 2010. Guide to the dissection of the dog. Seventh Edition, 45 p.
- KONING H. E. & LIEBICH H. G. 2006. Veterinary anatomy of domestic mammals Textbook and Colour Atlas. Third Edition.
- KUNZEL W., BREIT S. & OPPEL M. 2003. Morphometric investigation of breed specific features in feline skulls and considerations on their functional implications. *Anatomia, Histologia, Embryologia* 32: 218–223.
- MALLON D. P. 2008. *Gazella bennettii*. IUCN red list of threatened species. Version 2014.3. International Union for Conservation of Nature. Global survey and regional action plans. Gland, Switzerland: IUCN.
- MALLON D. P. & KINGWOOD S. C. 2001. Antelopes. Part 4: North Africa, the Middle East and Asia.
- MILLER M. E., CHRISTENSEN G. C. & EVANS H. E. 2013. Miller's Anatomy of the dog. Philadelphia: W.B. Saunders Co. pp. 716–718.
- NAHKUR E., ERNITS E., JALAKAS M. & JÄRV E. 2011. Morphological characteristics of pelvis of Estonian Holstein and Estonian native breed cows from the perspective of calving. *Anatomia, Histologia, Embryologia* 40 (5): 379–388.
- NICKEL R., SCHUMMER A. & SEIFERLE E. 2004. *Lehrbuch der Anatomie der Haustiere. Band I. Bewegungsapparat*. Stuttgart: Parey Verlag.
- NOMINA ANATOMICA VETERINARIA 2012. Fifth Edition. Prepared by the International Committee on Veterinary Gross Anatomical Nomenclature and Authorized by the General Assembly of the World Association of Veterinary Anatomists. Hannover & Sapporo, Japan: The Editorial Committee.
- NWOHA P. U. 2000. Sex differences in the bony pelvis of the fruit-eating bat, *Eidolon helvum*. *Folia Morphologica* 59: 291–295.
- OZKAN Z. E. 2002b. Macro anatomical investigations on the hind limb skeletons of hedgehog *Erinaceus europaeus*. II. Ossa Membri Pelvini. *Veterinarski Arhiv* 72 (4): 213–220.
- SAJJARENGPONG K., ADIREKTHAWORN A., SRISUWATTNASAGUL

- K., SUKJUMLONG S. & DARAWIROJ D. 2003. Differences seen in the pelvic bone parameters of male and female dogs. *Thai Journal of Veterinary Medicine* 33: 55–61.
- SARGIS E. J. 2002. Functional morphology of the hindlimb of tupaiids (Mammalia, Scandentia) and its phylogenetic implications. *Journal of Morphology* 254: 149–185.
- SMUTS M. & BEZUIDENHOUT A. J. 1987. *Anatomy of the dromedary*. Oxford, U.K.: Clarendon Press, pp: 24–47.
- SUDHAKAR L. S., SHARMA D. N. & BHARDWAJ R. L. 1997. Anatomy of hip bone Os coxae of yak *Bos grunniens*. *Indian Journal of Veterinary Anatomy* 9 (1/2): 53–56.
- VENTURA J., GOSALBEZ J. & GOTZENS V. J. 1991. The os coxae of a digging form of the northern water vole, *Arvicola terrestris* (Rodentia, Arvicolidae). *Anatomia, Histologia, Embryologia* 20: 225–236.
- YADAV S., MATHUR R., JOSHI S. & CHOUDHARY O. P. 2012. Gross and biometrical studies on pelvic bones of chital *Axis axis*. *Indian Journal of Veterinary Anatomy* 24 (2): 87–88.

Received: 30.04.2020

Accepted: 14.10.2020